

Childhood Tuberculosis

DR .JAYAPRAKASH.K.P,ASST PROF.ICH GOVT MEDICAL COLLEGE,KOTTAYAM

What is the magnitude of the problem?

India, the world's second most populous country, accounts for a quarter of the world's annual incidence of TB. **Every year around two million people develop TB in India and 300,000 die of TB.** Over 15 million patients have been treated and three million additional lives have been saved by the Revised National TB Control Programme (RNTCP) over the last decade. Cure rates have consistently been above 85% and the TB Millennium Development Goals are reachable

What is latent tuberculous infection?

Latent tuberculosis infection (LTBI) occurs after the inhalation of infective droplet nuclei containing *M. tuberculosis*. **A reactive tuberculin skin test (TST) and the absence of clinical and radiographic manifestations are the hallmark of this stage.** Untreated infants with LTBI have up to a 40% likelihood of developing tuberculosis, with the risk for progression decreasing gradually through childhood to adult lifetime rates of 5-10%. The greatest risk for progression occurs in the first 2 yr after infection.

How tb is transmitted?

Transmission of *M. tuberculosis* is person to person, usually by airborne mucus droplet nuclei, particles 1-5 μ m in diameter that contain *M. tuberculosis*. Transmission rarely occurs by direct contact with an infected discharge or a contaminated fomite. The chance of transmission increases when the patient has a positive acid-fast smear of sputum, an extensive upper lobe infiltrate or cavity, copious production of thin sputum, and severe and forceful cough. Environmental factors such as poor air circulation enhance transmission. Most adults no longer transmit the organism within several days to 2 weeks after beginning adequate chemotherapy, but some patients remain infectious for many weeks

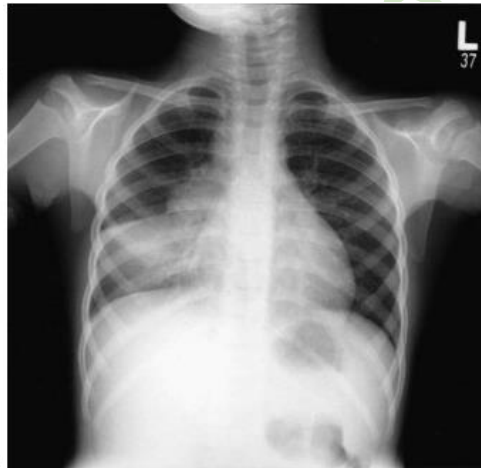
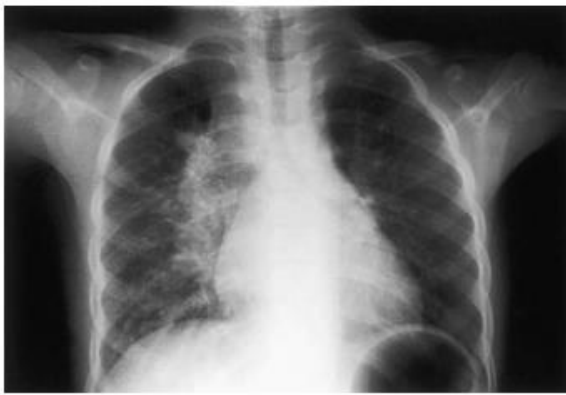Tubercle bacilli are sparse in the endobronchial secretions of children with pulmonary tuberculosis, and cough is often absent or lacks the tussive force required to suspend infectious particles of the correct size. Children and adolescents with adult-type cavitary or endobronchial pulmonary tuberculosis can transmit the organism

What is the pathogenesis of tuberculosis?

The primary complex of tuberculosis includes local infection at the portal of entry and the regional lymph nodes that drain the area The lung is the portal of entry in >98% of cases. The tubercle bacilli multiply initially within alveoli and alveolar ducts. Most of the bacilli are killed, but some survive within nonactivated macrophages, which carry them through lymphatic vessels to the regional lymph nodes.

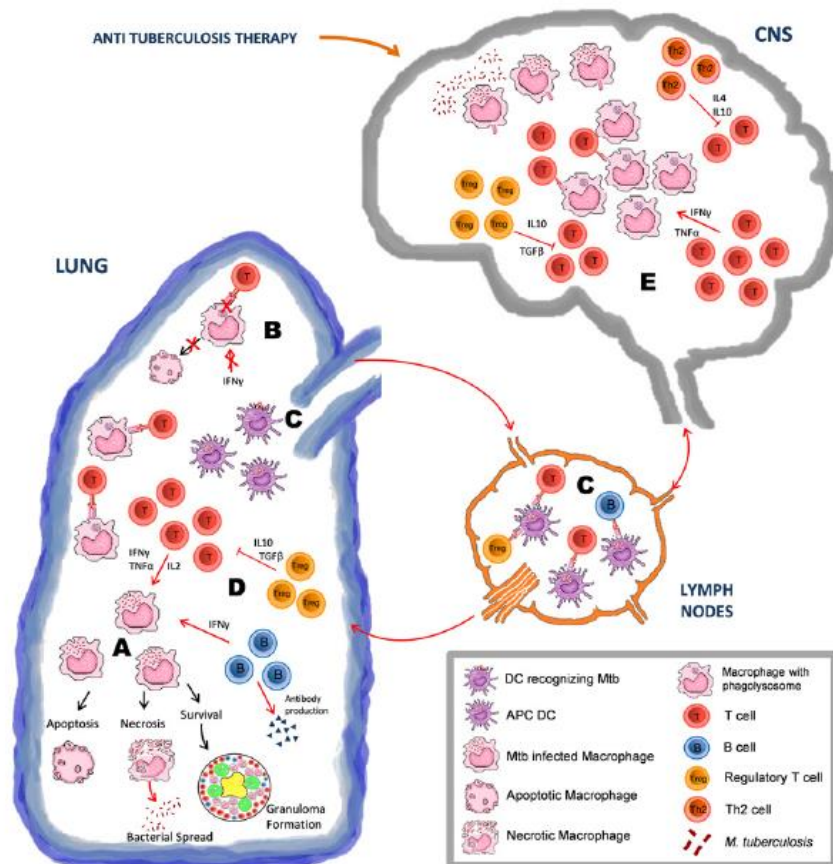
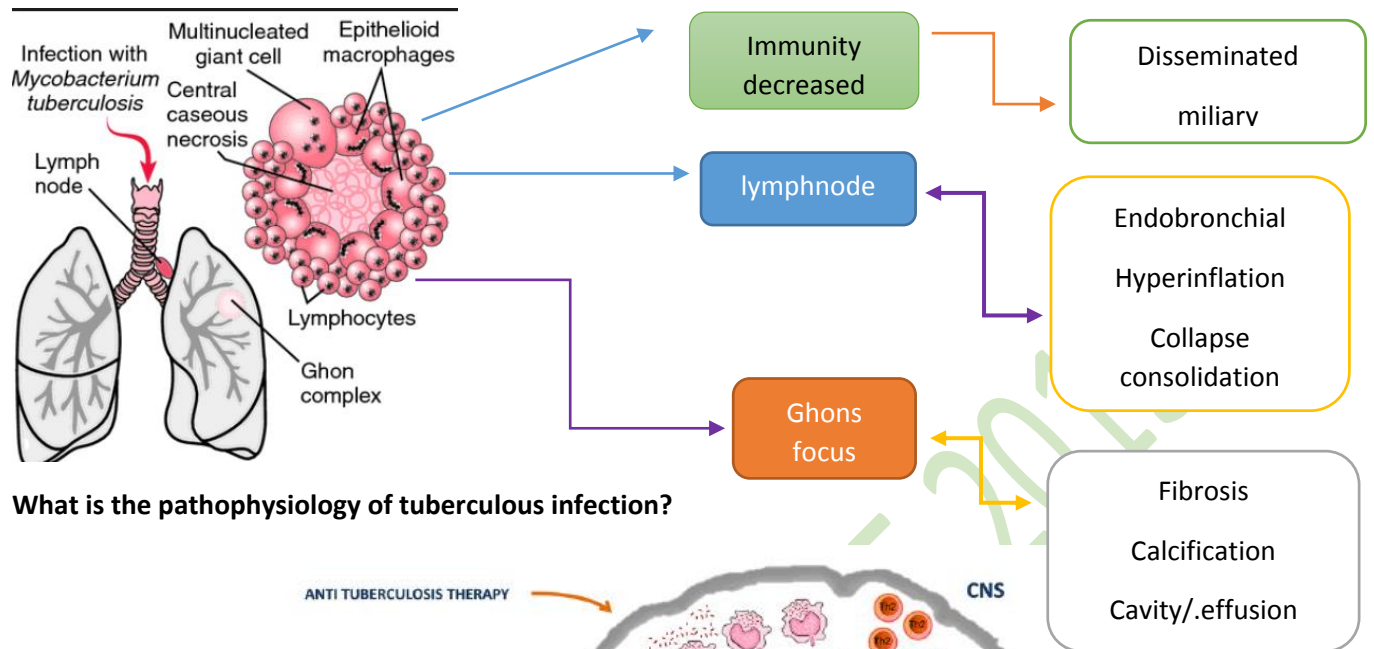
When the primary infection is in the lung, the hilar lymph nodes usually are involved, although an upper lobe focus can drain into paratracheal nodes. The tissue reaction in the lung parenchyma and lymph nodes intensifies over the next 2-12 wk as the organisms grow in number and tissue hypersensitivity develops. The parenchymal portion of the primary complex often heals completely by fibrosis or calcification after undergoing caseous necrosis and encapsulation. Occasionally, this portion continues to enlarge, resulting in focal pneumonitis and pleuritis. If caseation is intense, the center of the lesion liquefies and empties into the associated bronchus, leaving a residual cavity

The foci of infection in the regional lymph nodes develop some fibrosis and encapsulation, but healing is usually less complete than in the parenchymal lesion. Viable *M. tuberculosis* can persist for decades within these foci. In most cases of initial tuberculosis infection, the lymph nodes remain normal in size. However, hilar and paratracheal lymph nodes that enlarge significantly as part of the host inflammatory reaction can encroach on a regional bronchus **Partial obstruction of the bronchus** caused by external compression **can cause hyperinflation in the distal lung segment. Complete obstruction** results in **atelectasis**. Inflamed caseous nodes can attach to the bronchial wall and erode through it, causing **endobronchial tuberculosis or a fistula tract**. The caseum causes complete obstruction of the bronchus. The resulting lesion is a combination of pneumonitis and atelectasis and has been called a collapse-consolidation or segmental lesion



Disseminated tuberculosis occurs if the number of circulating bacilli is large and the host's cellular immune response is inadequate. More often the number of bacilli is small, leading to clinically inapparent metastatic foci in many organs. These remote foci usually become encapsulated, but they may be the origin of both extrapulmonary tuberculosis and reactivation tuberculosis in some persons.

The time between initial infection and clinically apparent disease is variable. Disseminated and meningeal tuberculosis are early manifestations, often occurring within 2-6 mo of acquisition. Significant lymph node or endobronchial tuberculosis usually appears within 3-9 mo. Lesions of the bones and joints take several years to develop, whereas renal lesions become evident decades after infection. **Extrapulmonary manifestations develop in 25-35% of children with tuberculosis, compared with about 10% of immunocompetent adults with tuberculosis**



The antimycobacterial immunological mechanisms in lungs, lymph nodes and in the brain. The innate immune response occurs in the lungs when macrophages and dendritic cells recognize bacteria and respond to the infection.

(A) **Macrophages can undergo necrosis or apoptosis, or they can survive**, leading to a bacterial spread and a latency state of the infection or, in the best scenario, help in bacterial elimination.

(B) **Mtb can evade the innate immune response leading to latency, by arresting the phagolysosome formation, inhibiting apoptosis as well as macrophage response to IFN γ stimuli.**

(C) **Resident dendritic cells that capture Mtb antigens activate T and B cells** as well as regulatory T cells.

(D) In the lungs, all activated T and B cells attracted by chemokines released by lung resident cell control bacterial growth. This control is done through the production of cytokines and antibodies respectively, whereas regulatory T cells help to control the inflammatory response producing IL10 and TGF β .

(E) During anti-tuberculous therapy or when the host immune response is activated, lymphocytes and infected macrophages can also enter the CNS, leading to an exacerbation of the inflammatory response, the so-called paradoxical reaction. Activation of the latent TB lesions increases antigen exposure and exacerbates the inflammatory T cell response against Mtb through the production of pro-inflammatory cytokines, such as TNF α or IFN γ . In this immune-privileged organ, the role of Tregs and Th2 cells may be of relevance to relieve the inflammatory response through the production of the anti-inflammatory cytokines IL10 and TGF β as well as IL4. Mtb: Mycobacterium tuberculosis; DC: Dendritic Cell; APC: Antigen-presenting cell.

When to suspect pulmonary tuberculosis?

Persistent Fever and/ or Cough >2 weeks AND/ OR

- Loss of weight / No weight gain¹ AND / OR
- History of contact with infectious TB case

1 History of unexplained weight loss or no weight gain in past 3 months; Loss of weight defined as loss of more than 5% body weight as compared to highest weight recorded in last 3 months

2. Radiological changes highly suggestive of TB are Hilar/paratracheal lymphadenitis with or without parenchymal lesion, Miliary TB, fibrocavitary pneumonia

What are the clinical manifestations of tb?

The majority of children with tuberculosis infection develop no signs or symptoms at any time.

Occasionally, infection is marked by low-grade fever and mild cough, and it is rarely marked by high fever, cough, malaise, and flulike symptoms that resolve within 1 wk

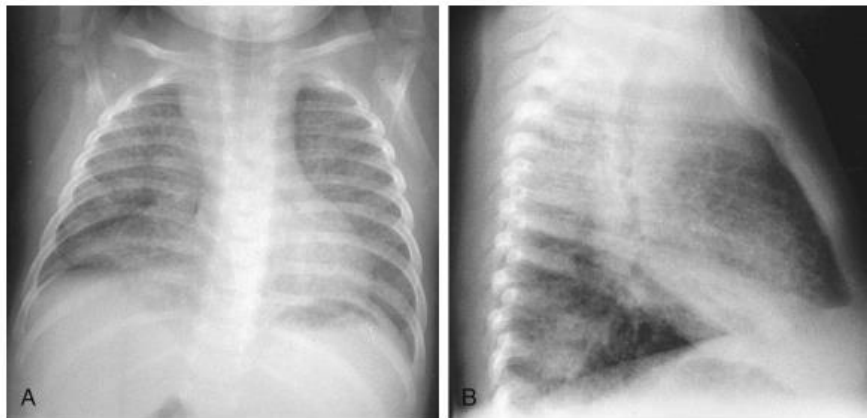
Primary Pulmonary Disease

The primary complex includes the parenchymal pulmonary focus and the regional lymph nodes. About 70% of lung foci are subpleural, and localized pleurisy is common. The initial parenchymal inflammation usually is not visible on chest radiograph, but a localized, nonspecific infiltrate may be seen before the development of tissue hypersensitivity. **The hallmark of primary tuberculosis in the lung is the relatively large size of the regional lymphadenitis compared with the relatively small size of the initial lung focus**

The usual sequence is hilar lymphadenopathy, focal hyperinflation, and then atelectasis. The resulting radiographic shadows have been called collapse-consolidation or segmental tuberculosis (. Rarely,

inflamed caseous nodes attach to the endobronchial wall and erode through it, causing endobronchial tuberculosis or a fistula tract. The caseum causes complete obstruction of the bronchus, resulting in extensive infiltrate and collapse

Children can have lobar pneumonia without impressive hilar lymphadenopathy. If the primary infection is progressively destructive, liquefaction of the lung parenchyma can lead to formation of a thin-walled primary tuberculosis cavity. Rarely, bullous tuberculous lesions occur in the lungs and lead to pneumothorax if they rupture. Erosion of a parenchymal focus of tuberculosis into a blood or lymphatic vessel can result in dissemination of the bacilli and a miliary pattern, with small nodules evenly distributed on the chest radiograph



The symptoms and physical signs of primary pulmonary tuberculosis in children are surprisingly meager considering the degree of radiographic changes often seen. When active case finding is performed, up to 50% of infants and children with radiographically moderate to severe pulmonary tuberculosis have no physical findings. Infants are more likely to experience signs and symptoms. Nonproductive cough and mild dyspnea are the most common symptoms. Systemic complaints such as fever, night sweats, anorexia, and decreased activity occur less often

The most specific confirmation of pulmonary tuberculosis is isolation of *M. tuberculosis*. Sputum specimens for culture should be collected from adolescents and older children who are able to expectorate. Induced sputum with a jet nebulizer and chest percussion followed by nasopharyngeal suctioning is effective in children as young as 1 mo. Sputum induction provides samples for both culture and smear staining, whereas gastric aspirates are usually cultured. even under optimal conditions, 3 consecutive morning gastric aspirates yield the organisms in <50% of cases

The presence of a positive TST or IGRA, an abnormal chest radiograph consistent with tuberculosis, and history of exposure to an adult with infectious tuberculosis is adequate proof that the disease is present

Progressive Primary Pulmonary Disease

A rare but serious complication of tuberculosis in a child occurs when the primary focus enlarges steadily and develops a large caseous center. Liquefaction can cause formation of a primary cavity associated with large numbers of tubercle bacilli. The enlarging focus can slough necrotic debris into the adjacent bronchus, leading to further intrapulmonary dissemination. Physical signs include diminished breath sounds, rales, and dullness or egophony over the cavity. The prognosis for full but usually slow recovery is excellent with appropriate therapy.

Older children and adolescents with reactivation tuberculosis are more likely to experience fever, anorexia, malaise, weight loss, night sweats, productive cough, hemoptysis, and chest pain than children with primary pulmonary tuberculosis. However, physical examination findings usually are minor or absent, even when cavities or large infiltrates are present. Most signs and symptoms improve within several weeks of starting effective treatment, although the cough can last for several months. This form of tuberculosis may be highly contagious if there is significant sputum production and cough. The prognosis for full recovery is excellent when patients are given appropriate therapy

Pleural Effusion

Tuberculous pleural effusions, which can be local or general, originate in the discharge of bacilli into the pleural space from a subpleural pulmonary focus or caseated lymph node. Asymptomatic local pleural effusion is so common in primary tuberculosis that it is basically a component of the primary complex. Larger and clinically significant effusions occur months to years after the primary infection. **Tuberculous pleural effusion is uncommon in children <6 yr of age and rare in children <2 yr of age. Effusions are usually unilateral but can be bilateral. They are rarely associated with a segmental pulmonary lesion and are uncommon in disseminated tuberculosis**

Clinical onset of tuberculous pleurisy is often sudden, characterized by low to high fever, shortness of breath, chest pain on deep inspiration, and diminished breath sounds. The fever and other symptoms can last for several weeks after the start of antituberculosis chemotherapy. The TST is positive in only 70-80% of cases. The prognosis is excellent, but radiographic resolution often takes months. Scoliosis is a rare complication from a long-standing effusion

Lymphohematogenous (Disseminated) Disease

Tubercle bacilli are disseminated to distant sites, including liver, spleen, skin, and lung apices, in all cases of tuberculosis infection. The clinical picture produced by lymphohematogenous dissemination depends on the quantity of organisms released from the primary focus and the adequacy of the host's immune response. **Lymphohematogenous spread is usually asymptomatic**

Multiple organ involvement is common, leading to hepatomegaly, splenomegaly, lymphadenitis in superficial or deep nodes, and papulonecrotic tuberculids appearing on the skin. Bones and joints or kidneys also can become involved. Meningitis occurs only late in the course of the disease

The most clinically significant form of disseminated tuberculosis is miliary disease, which occurs when massive numbers of tubercle bacilli are released into the bloodstream, causing disease in 2 or more organs. **Miliary tuberculosis usually complicates the primary infection, occurring within 2-6 mo of the**

initial infection. Although this form of disease is most common in infants and young children. Because this form of tuberculosis is most common in infants and malnourished or immunosuppressed patients, the host's immune incompetence probably also plays a role in pathogenesis

The onset of miliary tuberculosis is sometimes explosive, and the patient can become gravely ill in several days. More often, the onset is insidious, with early systemic signs, including anorexia, weight loss, and low-grade fever. At this time, abnormal physical signs are usually absent. Generalized lymphadenopathy and hepatosplenomegaly develop within several weeks in about 50% of cases. The fever can then become higher and more sustained, although the chest radiograph usually is normal and respiratory symptoms are minor or absent. Within several more weeks, the lungs can become filled with tubercles, and dyspnea, cough, rales, or wheezing occur. The lesions of miliary tuberculosis are usually smaller than 2-3 mm in diameter when first visible on chest radiograph

Diagnosis of disseminated tuberculosis can be difficult, and a high index of suspicion by the clinician is required. Often the patient presents with fever of unknown origin. Early sputum or gastric aspirate cultures have a low sensitivity. Biopsy of the liver or bone marrow with appropriate bacteriologic and histologic examinations more often yields an early diagnosis. The most important clue is usually history of recent exposure to an adult with infectious tuberculosis

Lymph Node Disease

Tuberculosis of the superficial lymph nodes, often referred to as scrofula, is the most common form of extrapulmonary tuberculosis in children. Historically, scrofula was usually caused by drinking unpasteurized cow's milk laden with *M. bovis*. **Most current cases occur within 6-9 mo of initial infection** by *M. tuberculosis*, although some cases appear years later. **The tonsillar, anterior cervical, submandibular, and supraclavicular nodes become involved secondary to extension of a primary lesion of the upper lung fields or abdomen.**

Infected nodes in the inguinal, epitrochlear, or axillary regions result from regional lymphadenitis associated with tuberculosis of the skin or skeletal system. The nodes usually enlarge gradually in the early stages of lymph node disease. They are discrete, nontender, and firm but not hard. The nodes often feel fixed to underlying or overlying tissue. **Disease is most often unilateral, but bilateral involvement can occur because of the crossover drainage patterns of lymphatic vessels in the chest and lower neck.** As infection progresses, multiple nodes are infected, resulting in a mass of matted nodes. Systemic signs and symptoms other than a low-grade fever are usually absent. **The TST is usually reactive, but the chest radiograph is normal in 70% of cases. The onset of illness is occasionally more acute, with rapid enlargement, tenderness, and fluctuance of lymph nodes and with high fever.** The initial presentation is rarely a fluctuant mass with overlying cellulitis or skin discoloration

Lymph node tuberculosis can resolve if left untreated but more often progresses to caseation and necrosis. The capsule of the node breaks down, resulting in the spread of infection to adjacent nodes. Rupture of the node usually results in a draining sinus tract that can require surgical removal.

Tuberculous lymphadenitis can usually be diagnosed by fine-needle aspiration of the node and responds well to antituberculosis therapy, although the lymph nodes do not return to normal size for

months or even years. Surgical removal is not usually necessary and must be combined with antituberculous medication because the lymph node disease is only one part of a systemic infection.

A definitive diagnosis of tuberculous adenitis usually requires histologic or bacteriologic confirmation, which is best accomplished by fine-needle aspiration for culture, stain, and histology. If fine-needle aspiration is not successful in establishing a diagnosis, excisional biopsy of the involved node is indicated. Culture of lymph node tissue yields the organism in only about 50% of cases. Many other conditions can be confused with tuberculous adenitis, including infection due to NTM, cat scratch disease (*Bartonella henselae*), tularemia, brucellosis, toxoplasmosis, tumor, branchial cleft cyst, cystic hygroma, and pyogenic infection. The most common problem is distinguishing infection due to *M. tuberculosis* from lymphadenitis caused by NTM in geographic areas where NTM are common

TB lymphadenitis

This is most common form of extra pulmonary tuberculosis. Clinical correlate of diagnosis includes progressive enlargement of lymph node for more than 2 weeks, firm, minimally tender or not tender, sometimes fluctuating, may be matted and may have chronic sinus formation. The diagnostic algorithm is shown below. Fine needle aspiration cytology (FNAC) is usually adequate for accurate diagnosis and it correlates well with biopsy in >90% of cases. Histopathology typically shows necrosis and epithelioid granuloma. It is important to look for AFB in FNAC specimen and it may be positive in 20-70% of patients. When FNAC is inconclusive, biopsy is necessary for confirmation of diagnosis. In children, lymphadenopathy is common due to recurrent tonsillitis and URIs as well. Such reactive lymphadenitis may clinically mimic tuberculosis but does not warrant anti-TB drugs. Persistent lymphadenopathy of significant size (say more than 2cm in the neck) should however, be investigated. TST is mostly positive in a significant proportion, but isolated skin test positivity is not enough to establish a diagnosis of TB. Hence anti-TB drugs should not be given unless the diagnosis of TB is confirmed by FNAC or histopathology.

Central Nervous System Disease

Tuberculosis of the central nervous system (CNS) is the most serious complication in children and is fatal without prompt and appropriate treatment. Tuberculous meningitis usually arises from the formation of a metastatic caseous lesion in the cerebral cortex or meninges that develops during the lymphohematogenous dissemination of the primary infection. **This initial lesion increases in size and discharges small numbers of tubercle bacilli into the subarachnoid space. The resulting gelatinous exudate infiltrates the corticomeningeal blood vessels, producing inflammation, obstruction, and subsequent infarction of cerebral cortex.** The brain stem is often the site of greatest involvement, which accounts for the commonly associated dysfunction of cranial nerves III, VI, and VII. The exudate also interferes with the normal flow of cerebrospinal fluid (CSF) in and out of the ventricular system at the level of the basilar cisterns, leading to a communicating hydrocephalus. The combination of

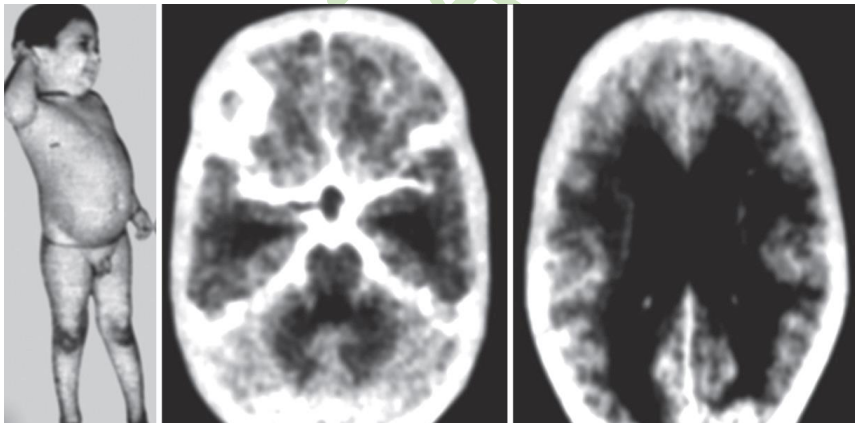
vasculitis, infarction, cerebral edema, and hydrocephalus results in the severe damage that can occur gradually or rapidly. Profound abnormalities in electrolyte metabolism due to salt wasting or the syndrome of inappropriate antidiuretic hormone secretion also contribute to the pathophysiology of tuberculous meningitis

The **1st stage** typically lasts 1-2 wk And is **characterized by nonspecific symptoms such as fever, headache, irritability, drowsiness, and malaise**. Focal neurologic signs are absent, but infants can experience a stagnation or loss of developmental milestones.

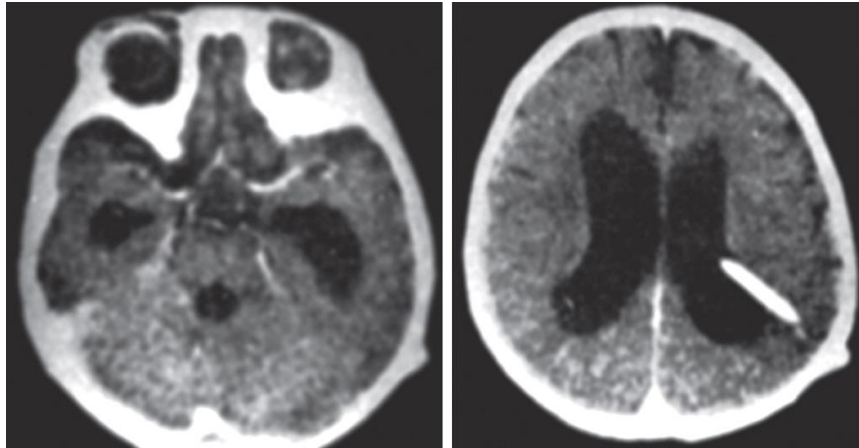
The **2nd stage** usually begins more abruptly. **The most common features are lethargy, nuchal rigidity, seizures, positive Kernig and Brudzinski signs, hypertonia, vomiting, cranial nerve palsies, and other focal neurologic signs**. The accelerating clinical illness usually correlates with the development of hydrocephalus, increased intracranial pressure, and vasculitis. Some children have no evidence of meningeal irritation but can have signs of encephalitis, such as disorientation, movement disorders, or speech impairment.

The **3rd stage** is marked by **coma, hemiplegia or paraplegia, hypertension, decerebrate posturing, deterioration of vital signs, and eventually death**

Grade	
I	Headache, vomiting, fever \pm neck stiffness No neurological deficit Normal sensorium
II	Normal sensorium Neurological deficit present
III	Altered sensorium but easily arousable Dense neurological deficit may or may not be present
IV	Deeply comatose Decerebrate or decorticate posturing



(A) Conscious child with TBM; (B) CT head showing dense basal exudates; (C) CT head showing basal exudates with improvement in hydrocephalus



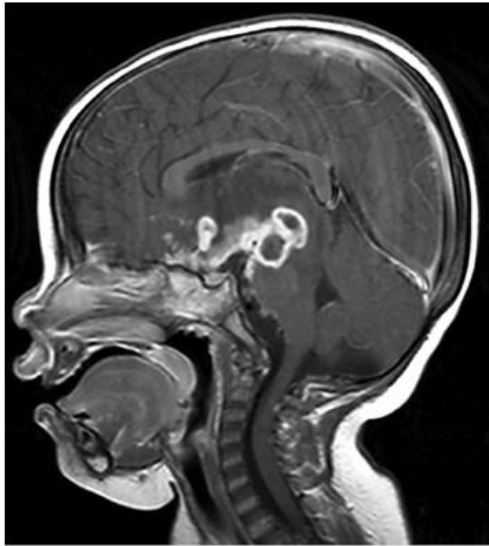Advanced TBM with hydrocephalus, multiple cranial nerve palsies, hemiplegia on right side and hemiballismus on the left but the child had complete recovery on treatment

The prognosis of tuberculous meningitis correlates most closely with the clinical stage of illness at the time treatment is initiated. The majority of patients in the 1st stage have an excellent outcome, whereas most patients in the 3rd stage who survive have permanent disabilities, including blindness, deafness, paraplegia, diabetes insipidus, or mental retardation. The prognosis for young infants is generally worse than for older children. It is imperative that antituberculosis treatment be considered for any child who develops basilar meningitis and hydrocephalus, cranial nerve palsy, or stroke with no other apparent etiology. Often the key to the correct diagnosis is identifying an adult who has infectious tuberculosis and is in contact with the child. Because of the short incubation period of tuberculous meningitis, the illness has not yet been diagnosed in the adult in many cases

Radiographic studies can aid in the diagnosis of tuberculous meningitis. **CT or MRI of the brain of patients with tuberculous meningitis may be normal during early stages of the disease. As disease progresses, basilar enhancement and communicating hydrocephalus with signs of cerebral edema or early focal ischemia are the most common findings.** Some small children with tuberculous meningitis can have one or several clinically silent tuberculomas, occurring most often in the cerebral cortex or thalamic regions.

Another manifestation of CNS tuberculosis is the tuberculoma, a tumor-like mass resulting from aggregation of caseous tubercles that usually manifests clinically as a brain tumor. Tuberculomas account for up to 40% of brain tumors in some areas of the world but are rare in North America. In adults tuberculomas are most often supratentorial, but **in children they are often infratentorial, located at the base of the brain near the cerebellum. Lesions are most often singular but may be multiple. The most common symptoms are headache, fever, and convulsions.** The TST is usually reactive, but the chest radiograph is usually normal. Surgical excision is sometimes necessary to distinguish tuberculoma from other causes of brain tumor. However, surgical removal is not necessary because most tuberculomas resolve with medical management. **Corticosteroids are usually administered during the 1st few weeks of treatment or in the immediate postoperative period to decrease cerebral edema. On CT or MRI of the brain, tuberculomas usually appear as discrete lesions with a significant amount of surrounding edema. Contrast medium enhancement is often impressive and can result in a ringlike**

lesion. Since the advent of CT, the paradoxical development of tuberculomas in patients with tuberculous meningitis who are receiving ultimately effective chemotherapy has been recognized. The cause and nature of these tuberculomas are poorly understood, but they do not represent failure of antimicrobial treatment. This phenomenon should be considered whenever a child with tuberculous meningitis deteriorates or develops focal neurologic findings while on treatment. Corticosteroids can help alleviate the occasionally severe clinical signs and symptoms that occur. These lesions can persist for months or even years.



Tuberculoma

Often seen in older children, it may present as a focal seizure in supra-tentorial cortical lesion or with symptoms and signs of raised intracranial tension with multiple localizing signs and hydrocephalus in posterior fossa lesion. It may sometimes also be seen as a part of TB meningitis. **Differentiation from other ring lesions, especially neurocysticercosis (NCC) is difficult in cortical lesion. A ring enhancing lesion is not pathognomonic of tuberculoma. A larger lesion > 20 mm, disc lesion or ring lesion with thicker rim with central nodule favors tuberculoma while multiple, smaller, thin rim with epicentric nodule favor NCC. MR spectroscopy may help in diagnosis of tuberculoma as it shows lipid peak.**

What is the criteria for dxing TBM?

Modified Ahuja criteria

A. Mandatory features

- Fever lasting for more than 14 days
- Abnormal CSF findings (pleocytosis with more than 20 cells and more than 60% lymphocytes, protein >100 mg/dl, sugar <60% of corresponding blood sugar values)

In addition to the above, any 2 of the following features

- Evidence of extra neural tuberculosis
- Positive family history of exposure to a case of tuberculosis
- Positive mantoux reaction (1 TU) >10 mm
- Abnormal CT scan findings (2 or more of following):
 - Exudate in the basal cistern or in the sylvian fissure
 - Hydrocephalus
 - Infarcts
 - Gyral enhancement

What are the investigations?

Tuberculous infection

Mantoux

IGRA

TUBERCULOUS DISEASE

Sputum afb/GASTRIC aspirate for afb

BACTEC/MGIT

Cxr

Ca –NAT

FNAC/BIOPSY

CSF

MRI/CT

What is mantoux?

A positive Tuberculin skin test / Mantoux positive were defined as 10 mm or more induration. The optimal strength of tuberculin 2 TU (RT 23 or equivalent) to be used for diagnosis in children.

The development of delayed-type hypersensitivity in most persons infected with the tubercle bacillus makes the TST a useful diagnostic tool. **The Mantoux TST is the intradermal injection of 0.1 mL purified protein derivative stabilized with Tween 80. T cells sensitized by prior infection are recruited to the skin, where they release lymphokines that induce induration through local vasodilation, edema, fibrin deposition, and recruitment of other inflammatory cells to the area. The amount of induration in response to the test should be measured by a trained person 48-72 hr after administration.** In some patients, the onset of induration is longer than 72 hr after placement; this is also a positive result. Immediate hypersensitivity reactions to tuberculin or other constituents of the preparation are short-lived (<24 hr) and not considered a positive result.

Tuberculin sensitivity develops 3 wk to 3 mo (most often in 4-8 wk) after inhalation of organisms. Host-related factors, including very young age, malnutrition, immunosuppression by disease or drugs, viral infections (measles, mumps, varicella, influenza), vaccination with live-virus vaccines, and overwhelming tuberculosis, can depress the skin test reaction in a child infected with M. tuberculosis. Corticosteroid therapy can decrease the reaction to tuberculin, but the effect is variable. TST done at the time

what is IGRA?

Interferon- γ Release Assays

Two blood tests (T-SPOT.TB and QuantiFERON-TB) detect IFN- γ generation by the patient's T cells in response to specific M. tuberculosis antigens (ESAT-6, CFP-10, and TB7.7). The QuantiFERON-TB test

measures whole blood concentrations of IFN- γ , and the T-SPOT.TB test measures the number of lymphocytes/monocytes producing IFN- γ . The test antigens are not present on M. bovis-BCG and Mycobacterium avium complex, the major group of environmental mycobacteria, so one would expect higher specificity compared with the TST and fewer false-positive results. Both IGRAs have internal positive and negative controls. Like the TST, IGRAs cannot differentiate between tuberculosis infection and disease. Two clear advantages of the IGRAs are the need for only 1 patient encounter (vs 2 with the TST) and the lack of crossreaction with BCG vaccination and most other mycobacteria.

IGRAs should be interpreted with caution when used for children younger than 5 yr of age and immunocompromised patients owing to the relative lack of data and the increased propensity for indeterminate results in these groups, making TSTs preferred in these populations.

IGRAs are preferred and TSTs are considered acceptable in the BCG-immunized older child (≥ 5 yr) and in those ≥ 5 yr who are unlikely to return for TST reading. Both TST and IGRA testing should be obtained in children with an indeterminate initial and repeat IGRA testing; in those in whom initial TST or IGRA testing is negative and the suspicion for tuberculosis disease or risk of progression to disease is high; in those ≥ 5 yr who have a positive TST and have received the BCG vaccine; in those whose family is reluctant to treat infection based on a TST result alone; and in those in whom nontuberculous mycobacterial disease is suspected. As most studies have not shown a consistent, significant difference between the IGRAs, the CDC recommends that the assays may be used interchangeably.

what is the role of nucleic acid amplification?

Nucleic Acid Amplification

The main form of nucleic acid amplification studied in children with tuberculosis is PCR, which uses specific DNA sequences as markers for microorganisms. Evaluation of PCR in childhood tuberculosis has been limited. Compared with a clinical diagnosis of pulmonary tuberculosis in children, the sensitivity of PCR has varied from 25-83%, and specificity has varied from 80-100%. A negative PCR result never eliminates the diagnosis of tuberculosis, and the diagnosis is not confirmed by a positive PCR result.

Gene Xpert MTB/RIF is a real-time PCR assay for *M. tuberculosis* that simultaneously detects rifampin resistance, which is often used as a proxy for MDR tuberculosis. This assay uses a self-contained cartridge system, which yields results from direct specimens in 2 hr and is less operator dependent than traditional PCR detection methods.

Sensitivity and specificity were 72-77% and 99% in smear-negative adults and 98-99% and 99-100% in smear-positive adults, respectively. Pediatric studies reveal that compared to smear microscopy, this technology has superior diagnostic capability on direct sputum and gastric aspirates. Although cartridges for the Xpert system are expensive, it offers advantages in rapid detection of MDR tuberculosis and is especially useful in settings lacking laboratory infrastructure. Xpert should never replace mycobacterial cultures.

What is the role of culture?

Mycobacteria grow slowly, with a generation time of 12-24 hr. Isolation from clinical specimens on solid **synthetic media usually takes 3-6 wk, and drug susceptibility testing requires an additional 4 wk.** **Growth can be detected in 1-3 wk in selective liquid medium using radiolabeled nutrients (e.g., the BACTEC radiometric system) or MGIT, and drug susceptibilities can be determined in an additional 3-5 days.** Once mycobacterial growth is detected, the species of mycobacteria present can be determined within hours using high-pressure liquid chromatography analysis (based on the fact that each species has a unique fingerprint of mycolic acids) or DNA probes

WHAT IS THE ROLE OF CSF?

1. **Typically CSF is clear to opalescent, usually does not show very high cell count (under 500 cells/mm³) with lymphocytosis. Biochemical investigations reveal increased proteins and mild reduction in glucose.** The typical CSF picture may, however, not always be seen. Furthermore, the typical CSF picture described above can also be mimicked by partially treated pyogenic meningitis. In such a situation, reassessing after 48-72 hours of treatment with a fresh set of broad spectrum potent antibiotics to evaluate improvement in clinical status as well as in CSF can be useful.

2. Efforts should be made to establish the diagnosis by collecting more supportive evidence using TST, chest skiagrams. Bacteriological diagnosis from appropriate samples including CSF is diagnostic. Many a time concomitant TB lesions elsewhere in the body (say, pulmonary) coexist and can clinch the diagnosis. **Mycobacterial culture from CSF should also be attempted but CSF culture has poor sensitivity (16%) though specificity is high (90%).**

3. **Neuroimaging is an important diagnostic modality. It may reveal one or more of the following findings: basal meningeal enhancement; hydrocephalus with or without peri-ventricular ooze; tuberculoma(s); or infarcts may be seen in different areas, especially in basal ganglia.**

4. **Normal CT scan does not rule out TBM** and in case of strong clinical suspicion of diagnosis, a repeat follow-up CT scan after few days may show newly developing lesions. CSF abnormalities in TBM may take variable time up to few months to return to normal.

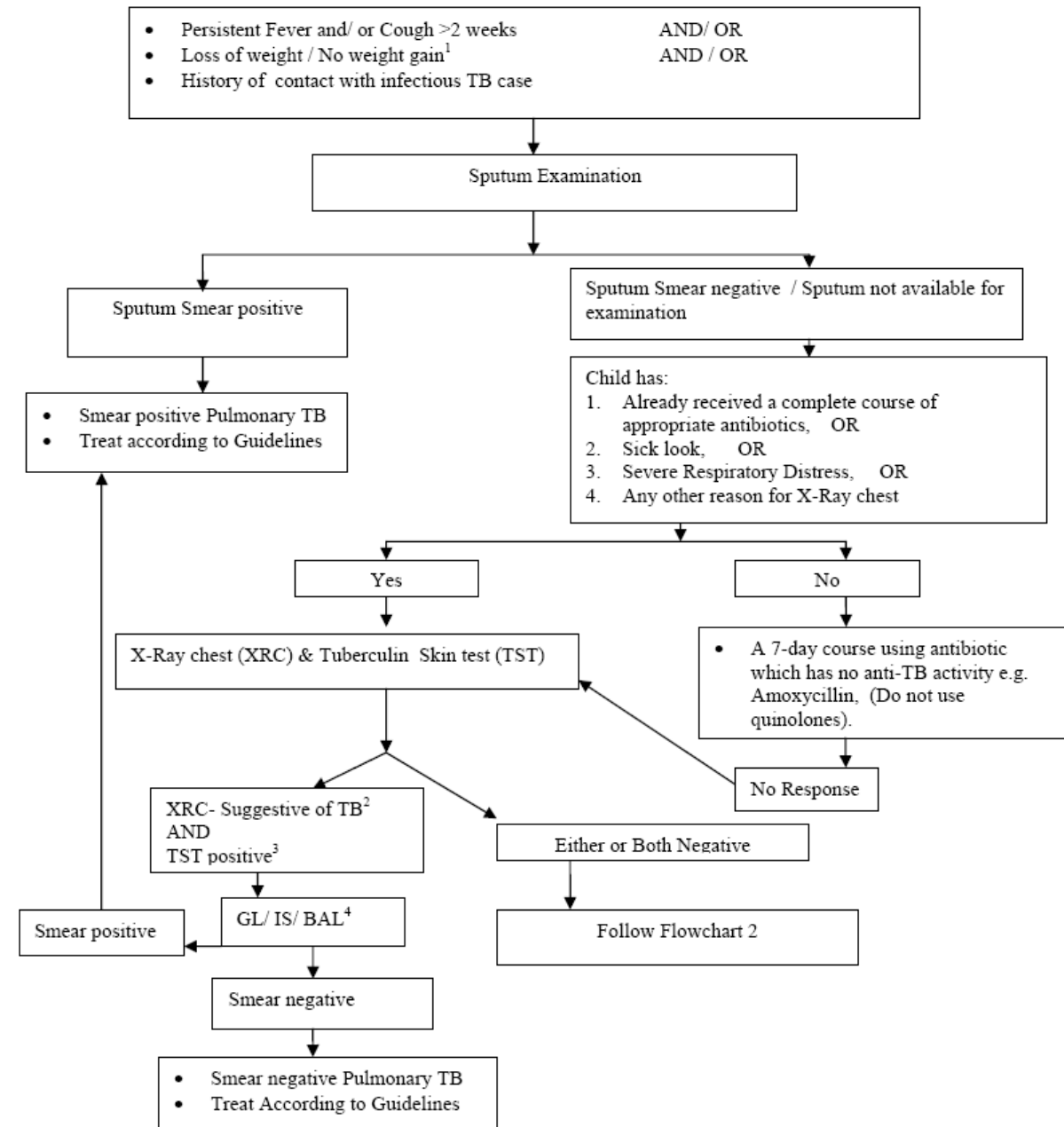
5. Besides routine CSF examination, **CSF ADA is high in TBM**. Various studies have a cut-off point between 7 and 11.3 IU/L for diagnosis. This may offer supportive evidence in favor of TBM but should not be taken in isolation.

6. CSF antigen and PCR tests are neither routinely available nor reproducible. They are, therefore, not recommended. CSF antibody tests have poor sensitivity and specificity and hence are not useful.

WHAT IS THE ALGORITHM FOR PULMONARY TB?

Diagnostic Algorithm for Pediatric Pulmonary Tb

Flowchart 1

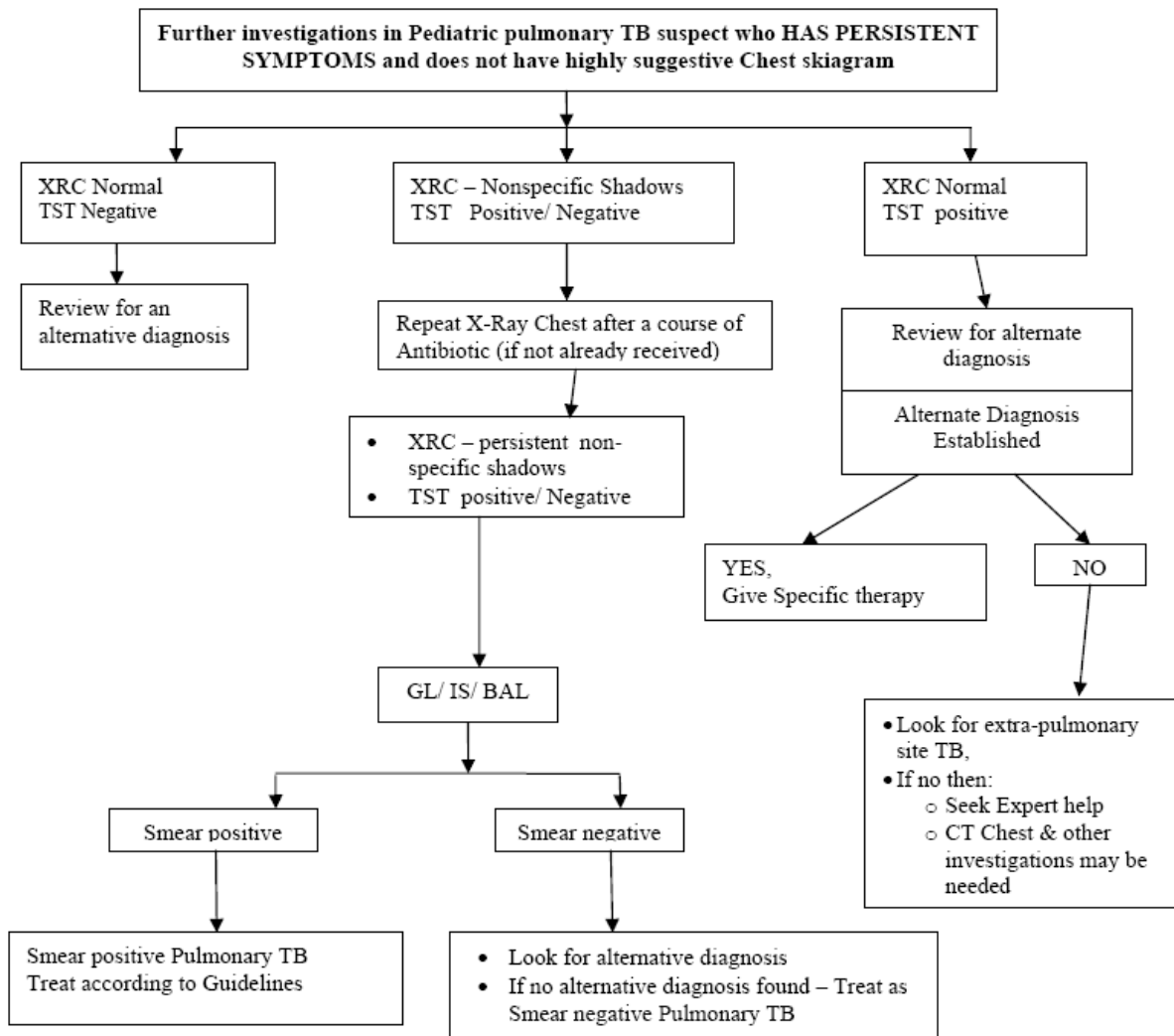


¹History of unexplained weight loss or no weight gain in past 3 months; Loss of weight defined as loss of more than 5% body weight as compared to highest weight recorded in last 3 months.

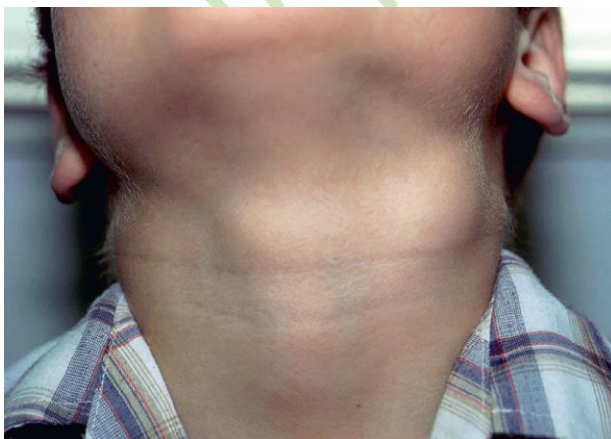²Radiological changes highly suggestive of TB are Hilar/paratracheal lymphadenitis with or without parenchymal lesion, Miliary TB, fibrocavitary pneumonia.

³If the radiological picture is highly suggestive of TB, then proceed to do further investigations irrespective of the TST result as the sensitivity of the test is not 100%.

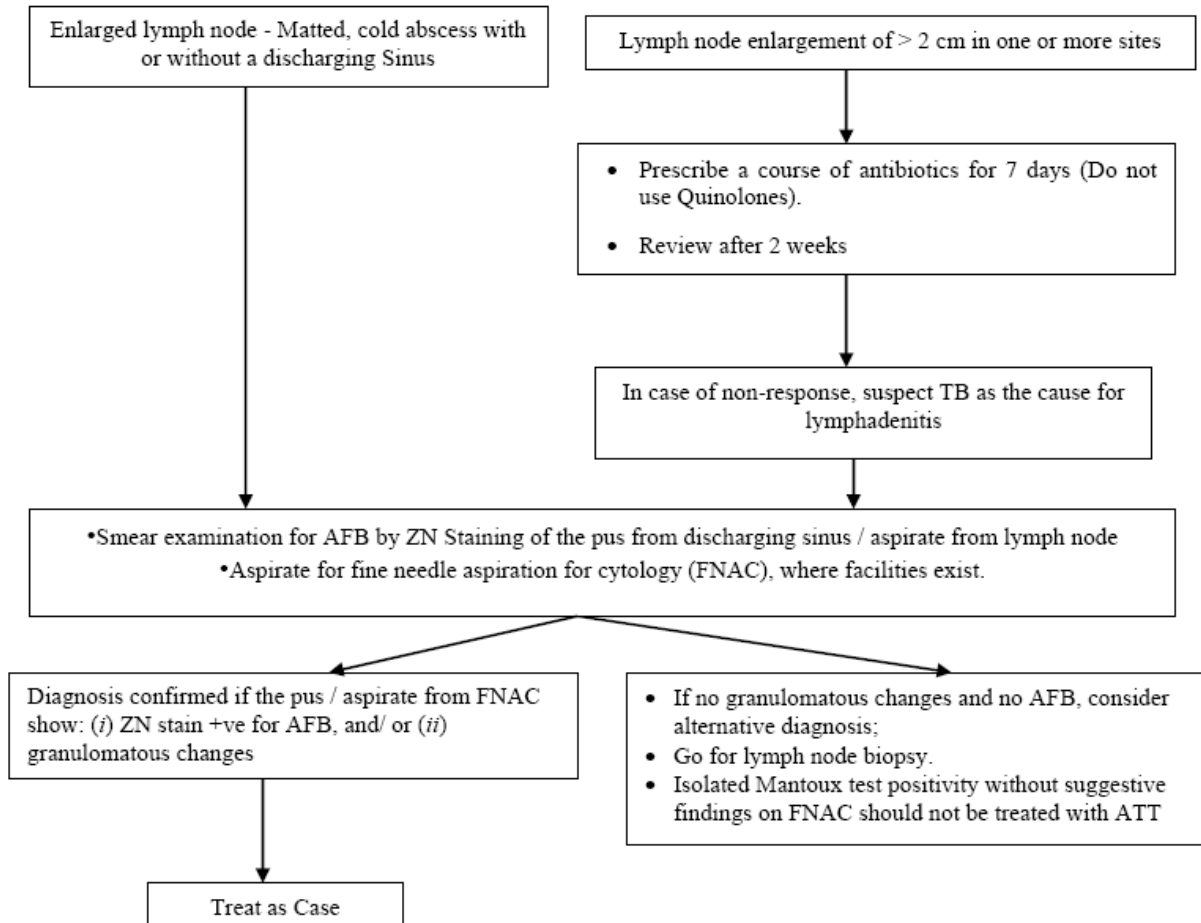
⁴All efforts including Gastric Lavage (GL)/ Induced sputum (IS) or Bronchoalveolar lavage (BAL) should be made to look for Acid fast bacilli (AFB) depending upon the facilities.



WHAT IS THE ALGORITHM FOR LYMPHNODE TB?



Diagnostic algorithm for diagnosis of Lymph Node Tuberculosis



HOW DO YOU DX PLEURAL EFFUSION?

If chest X-ray is suggestive of pleural effusion, pleural aspiration should always be performed for biochemical, cytological and smear examination by ZN stain to confirm the diagnosis. Typically, atubercular effusion fluid is straw colored (pus, if aspirated, is very rarely due to TB etiology) **has large numbers of cells (in hundreds; predominantly mononuclear), with high proteins (>3g/dL). Adenosine Deaminase (ADA) levels over 60 IU/L may be suggestive of tuberculous pleural effusion** but is not diagnostic of TB. Pleural biopsy may be performed, where available, particularly when the fluid aspirate findings are inconclusive.

WHAT IS TB PREVENTIVE THERAPY?

TB preventive therapy: **The dose of INH for chemoprophylaxis is 10 mg/kg (instead of currently recommended dosage of 5 mg/kg) administered daily for 6 months.** TB preventive therapy should be provided to:

a. All asymptomatic contacts (under 6 years of age) of a smear positive case, after ruling out active disease and irrespective of their BCG or nutritional status.

b. Chemoprophylaxis is also recommended for all HIV infected children who either had a known exposure to an infectious TB case or are Tuberculin skin test (TST) positive (≥ 5 mm induration) but have no active TB disease.

c. All TST positive children who are receiving immunosuppressive therapy (e.g. Children with nephrotic syndrome, acute leukemia, etc.).

d. A child born to mother who was diagnosed to have TB in pregnancy should receive prophylaxis for 6 months, provided congenital TB has been ruled out. BCG vaccination can be given at birth even if INH chemoprophylaxis is planned

WHAT IS THE TREATMENT?

Intermittent versus Daily regimen:

The intermittent therapy will remain the mainstay of treating pediatric patients. However, Among seriously ill admitted children or those with severe disseminated disease/ neurotuberculosis, the likelihood of vomiting or non-tolerance of oral drugs is high in the initial phase. Such, select group of seriously ill admitted patients should be given daily supervised therapy during their stay in the hospital using daily drug dosages. After discharge they will be taken on thrice weekly DOT regimen (with suitable modification to thrice weekly dosages).

The following are the daily doses (mg per kg of body weight per day) Rifampicin 10-12 mg/kg (max 600 mg/day), Isoniazid 10 mg/kg (max 300 mg/day), Ethambutol 20-25mg/kg (max 1500 mg/day), PZA 30-35mg/kg (max 2000 mg/day) and Streptomycin 15 mg/kg (max 1gm/day).

PULMONARY

CATEGORY 1

INTENSIVE PHASE- 2HRZE (INTERMITTANT)

CONTINUATION- 4HR (INTERMITTANT)

TB Meningitis:

During intensive phase of TB Meningitis, Injection Streptomycin is to be replaced by Tablet Ethambutol.

Extending intensive and continuation phase:

a. Children who show poor or no response at 8 weeks of intensive phase should be given benefit of extension of IP for one more month.

b. In patients with TB Meningitis, spinal TB, miliary/disseminated TB and osteoarticular TB, the continuation phase shall be extended by 3 months making the total duration of treatment to a total of 9 months. A further extension may be done for 3 more months in continuation phase (making the total duration of treatment to 12 months) on a case to case basis in case of delayed response and as per the discretion of the treating physician/ pediatrician

TABLE 3: Treatment Categories and Regimens for Childhood Tuberculosis			
Category of treatment	Type of patients	TB treatment regimens	
		Intensive phase	Continuation phase
New cases	<ul style="list-style-type: none"> New smear-positive pulmonary Tuberculosis (PTB) New smear-negative PTB New extra-pulmonary TB. 	2H ₃ R ₃ Z ₃ E ₃ *	4H ₃ R ₃
Previously treated cases	<ul style="list-style-type: none"> Relapse, failure to respond or treatment after default Re-treatment Others 	2S ₃ H ₃ R ₃ Z ₃ E ₃ + 1H ₃ R ₃ Z ₃ E ₃	5H ₃ R ₃ E ₃
H=Isoniazid, R= Rifampicin, Z= Pyrazinamide, E= Ethambutol, S= Streptomycin			

WHAT IS MDR TB?

MDR-TB Case: An MDR-TB suspect who is sputum culture positive and has *M. tuberculosis* resistant to isoniazid and rifampicin, with or without resistance to other anti-tubercular drugs based on DST results from an RNTCP accredited laboratory.

WHAT IS XDR

Resistance to inh,rifampicin,one of the quinolones, and one injectable aminoglycoside

What is the treatment?

The treatment is given in two phases, the Intensive phase (IP) and the Continuation phase (CP). IP should be given for at least six months. After 6 months of treatment, the patient will be reviewed and the treatment changed to CP if the 4th month culture result is negative. If the 4th month culture result remains positive, the treatment is extended by 1 month. Extension of IP beyond 1 month will be decided on the results of sputum culture of 5th and 6th months. If the result of the 4th month culture is still awaited after 6 months of treatment,the IP is extended until the result is available, with further treatment being decided according to the cultureresult. The IP can be extended up to a maximum of 3 months after which the patient will be initiated on the **CP irrespective of the culture result. The recommended duration for CP is 18 months**

RNTCP will be using a Standardised Treatment Regimen (Cat IV) for the treatment of MDR-TB cases (andthose with rifampicin resistance) under the programme. Cat IV regimen comprises of 6 drugs- kanamycin,ofloxacin (levofloxacin)[†], ethionamide, pyrazinamide, ethambutol and cycloserine during 6-9 months of the Intensive Phase and 4 drugs- ofloxacin (levofloxacin), ethionamide, ethambutol and cycloserine during the 18 months of the Continuation Phase. p-aminosalicylic acid (PAS) is included in the regimen as a substitute drug if any bactericidal drug (K, OfI, Z and Eto) or 2 bacteriostatic (E and Cs) drugs are not tolerated

RNTCP CATEGORY IV REGIMEN: 6 (9) Km Ofx (Lv_x) Eto Cs Z E / 18 Ofx (Lv_x) Eto Cs E